Mrs Campbell

BTEC Sport

13F
Carla Hill

Assignment 4

Structure of the respiratory system

Nasal Cavity

The nose can vary in different shapes, size and colours. The nose is divided into the internal nasal cavity and the external nasal cavity. The two cavities are parted into the left and right cavity. The centre of this is called the nasal septum. When you breathe in, it goes threw the nose, then the air is filtered by little hairs inside the nose which trap dirt and pollen. The walls are covered in tissue inside your nasal cavity are filled with blood vessels. The heat from your blood vessels helps heat up the air that you breathe.

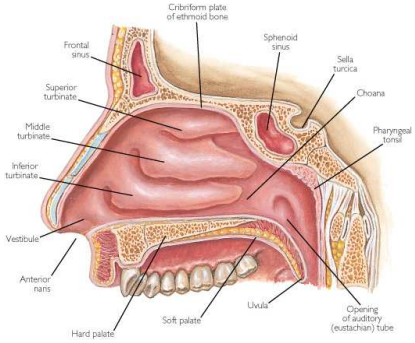

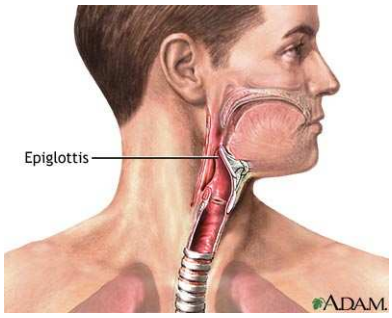

Epiglottis

This is a small flap like structure which is made of cartilage. It closes the top of the trachea when you swallow food or drink to ensure it doesn't go down into the lungs.

Pharynx

The pharynx is a tube like structure which connects to the nasal and oral cavities. It is also sometimes called the throat. It is a small tube that is normally around 10-13cm from the base of the skull to the end. It is a tube for food and air so special features allow food to travel down this tube into another opening for food and there is another opening for air.

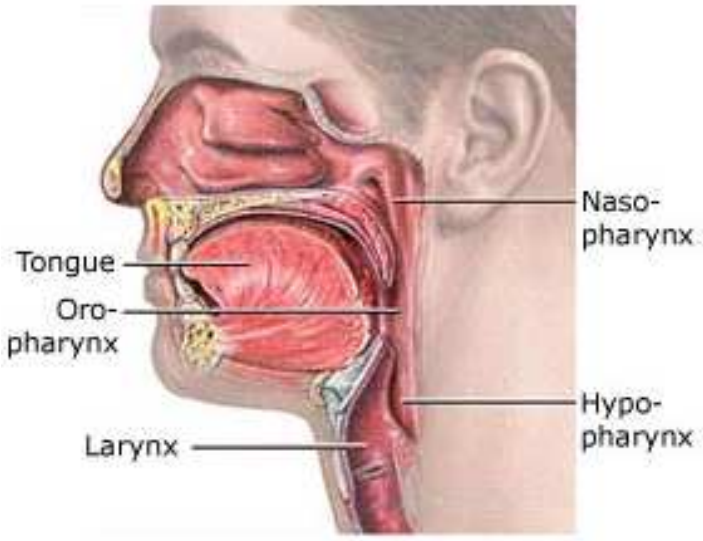

Larynx

The larynx is commonly called the voice box, is an organ in the neck which protects the trachea and the sound production. It is also

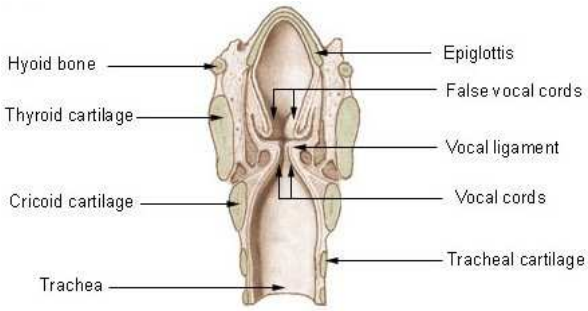

sometime's called 'Adam's apple'. It controls the volume and pitch. The main function of the larynx is the sound production. The strength from the lungs also contributes to the loudness. It is shaped like a funnel, made of cartilage with a complicated system of different sizes and lengths of muscles.
It is usually divided into three sections: sublarynx, larynx, and supralarynx. It is formed by nine cartilages, the epiglottis, thyroid, cricoid, arytenoid (two), corniculate (two), and cuneiform (two).
http://www.daviddarling.info/encyclopedia/L/larynx.html
http://en.wikipedia.org/wiki/Larynx

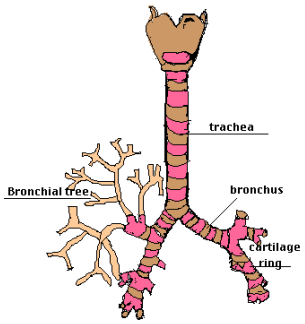

Trachea
The trachea begins below the larynx and runs down the neck and ends at the top part of the sternum. It then branches off into the right and left bronchi. It is about 12cm by 2cm in diameter. The trachea is a bony tube which connects from the nose and mouth to the lungs. The bony tube is made of cartilage and ligaments. It is made of cartilage to prevent it from collapsing although it is very flexible.
http://www.innerbody.com/image_card06/card13.html
http://library.thinkquest.org/5777/images/41b.gif

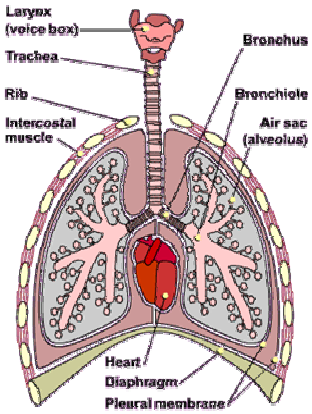

Bronchus
The bronchus is formed by the division of the trachea. The left and right lungs both have one large bronchus, which connects to the trachea. Bronchi have cartilage plates, soft muscle and mucus-secreting gland-cells in its wall. These carry air to the lungs. The left bronchus is smaller than the right bronchus which is shorter and wider so foreign objects are more likely to become lodged in the left bronchi. The whole bronchi system is known as 'The bronchial tree'.
http://www.daviddarling.info/encyclopedia/B/bronchus.html
http://en.wikipedia.org/wiki/Bronchus

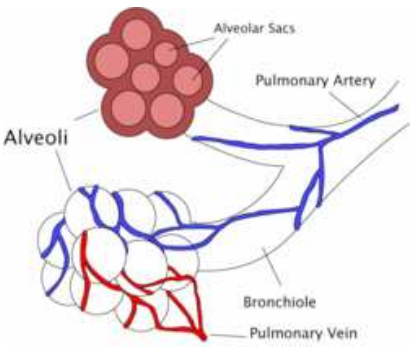

Bronchioles
These are passages within the lungs. They branch off as large bronchi and become smaller and thinner. The diameter is very important to airflow. They change diameter is reduce or increase airflow. An increase in diameter is called

bronchodilation. A decrease in diameter is called bronchoconstriction.
http://www.probertencyclopaedia.com/cgi-bin/res.pl?keyword=Bronchioles&offset=0
http://en.wikipedia.org/wiki/Bronchiole

Lungs

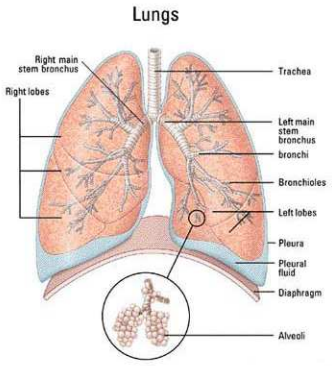

The lungs are a very important part of the respiratory system. The left lung is smaller than the right lung. The extra room on the left side gives room for your heart. The lungs are located in the chest area and take up most of the area in your chest. The lungs are protected by your rib cage which also protects the heart. Beneath your lungs is the diaphragm. This helps your lungs to inhale and exhale air. You cannot feel your lungs but you can feel them when you are breathing in and out.

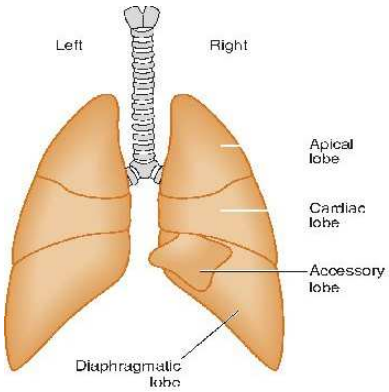

http://kidshealth.org/kid/htbw/lungs.html
http://en.wikipedia.org/wiki/Human_lung

Lobes

The left and right lung is divided into lobes. The lung on the right has 3 lobes and the one on the left has 2. There is less lobes in the left lung because the heart is taking up some room where there may be one more lobe.

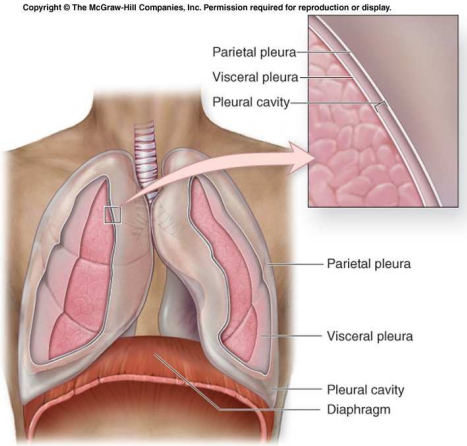

Pleural membrane

The lungs are surrounded by membranes. These are known as pleura. The membranes cover the lungs in two layers. Between the two layers is a small space. This is called the pleura cavity.

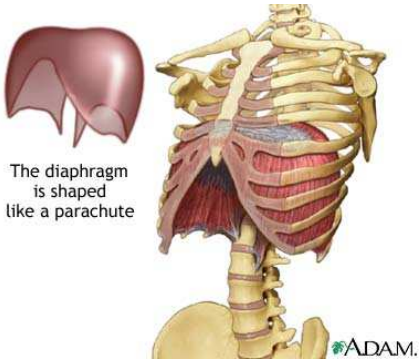

Thoracic cavity

From the neck to the chest is the thoracic cavity, which runs from the bottom of the neck down to the end of the ribs, or the diaphragm. This is a chamber of the chest which is protected by the thoracic

wall. It is separated from the abdominal cavity by the diaphragm.
BTEC Sport Level 3 Book 1 Pg 27.

Visceral pleura

The lungs are surrounded by two membranes. The outer layer is attached to the chest wall and this is called the parietal pleura. And the inner membrane is attached to the lung and other tissues. Unlike the parietal pleura the visceral pleura is not sensitive to pain.

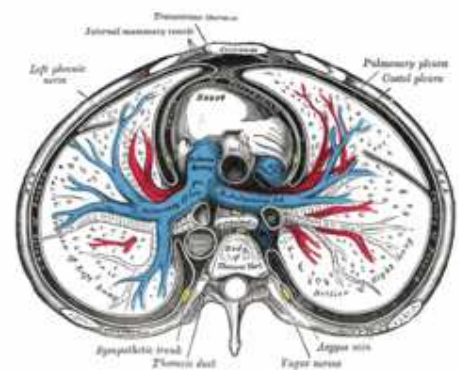

Thoracentesis, http://www.webmd.com/a-to-z-guides/Thoracentesis, Webmd.com
J Toxicol Environ Health. 1985;15(5):673-86., R.F. Dodson
http://www.asbestos.net/medical-glossary/visceral-pleura.html

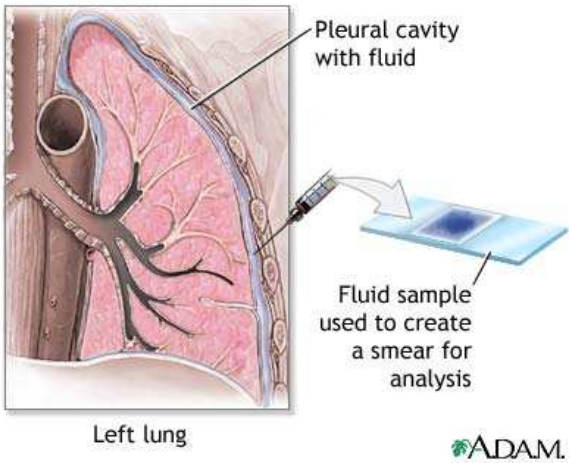

Pleural fluid

The excess fluid in the lungs and chest cavity is known as pleural fluid (effusion). This fluid is slowly produced by the body in very small amounts. It is used to line the lungs and chest cavity which enables breathing. If excess fluid is produced, this is usually classed as a disorder or a disease.

http://medicalimages.allrefer.com/large/pleural-smear.jpg

Alveoli

At the end of every alveolar duct, there are sac-like structures called alveoli. They are all grouped together like little caves and they produce surfactant. The exchange of carbon dioxide and oxygen take place in these cave-like structures. The oxygen is called away by

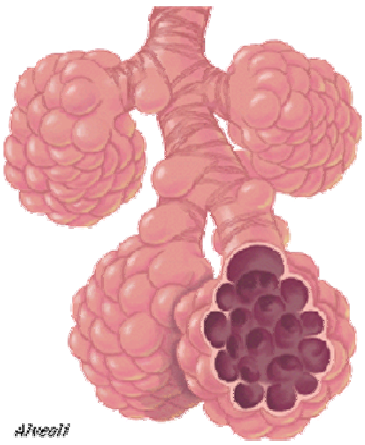

the body's tissues. The carbon dioxide is produced by the body's metabolism.
http://oac.med.jhmi.edu/res_phys/Encyclopedia/Alveoli/Alveoli.HTML
http://www.curoservice.com/parents_visitors/lungs_circulation/structure_alveoli.asp

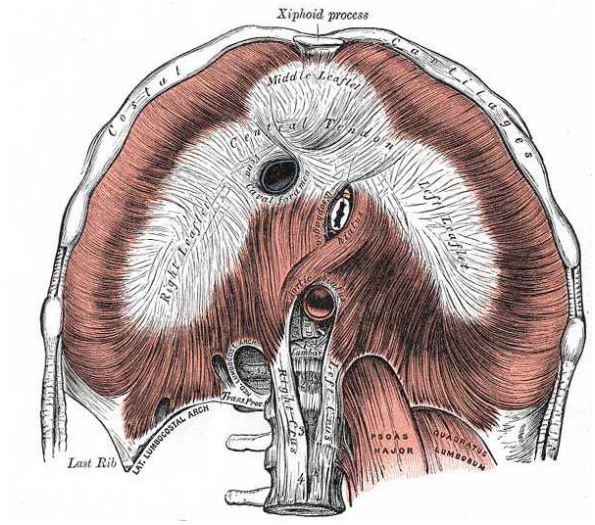

Diaphragm
The diaphragm is the most important muscle in the respiratory system. It is a sheet of muscle which is stretched across the bottom of the rib cage. The diaphragm separates the heart, lungs and ribs from the abdominal. The diaphragm functions in breathing. The diaphragm also helps you to vomit, urinate and pass faeces.
http://en.wikipedia.org/wiki/Thoracic_diaphragm
http://anatomy.med.umich.edu/images/diaphragm.jpg

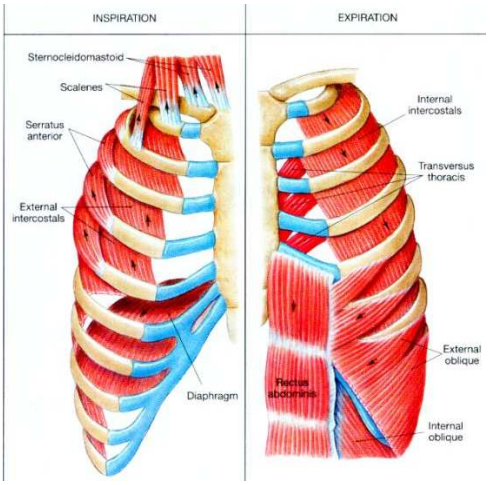

Intercostal muscles
Internal
These are located around the rib cage and are responsible for the depression of the ribs. This is the lower section of the muscles.
External
This is responsible for the evaluation of the rib, and expanding the top section of the ribs.

http://www.pilatespatio.com/external_internal_intercostals.jpg

Gaseous exchange

This is the main function of the respiratory system. This means oxygen and carbon dioxide travelling between the lungs and the blood.
http://www.teachpe.com/anatomy/gas_exchange.php

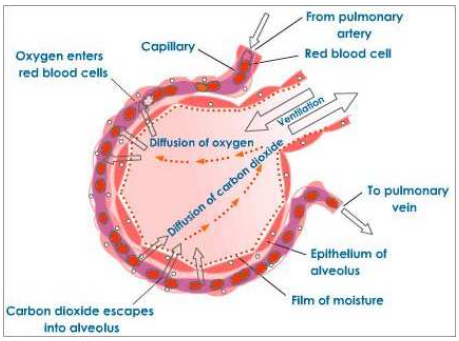

Mechanisms of breathing

Inspiration

During inspiration, the sternum and ribs move upwards and outwards. Also, the width of the chest increases from side to side, from front to back and from bottom to top. Also the diaphragm descends and the dept of the chest increases.

Expiration

The ribs and the sternum move downwards and inwards, while the width of the chest contracts. The diaphragm relaxes, and it ascends and the dept of the chest contracts.

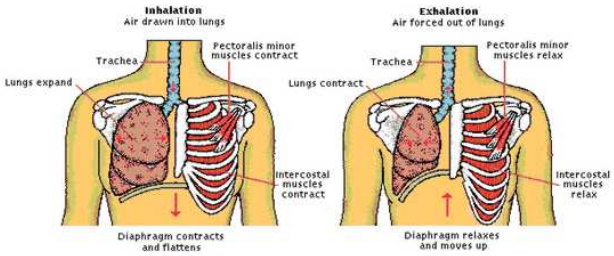

http://www.ranganaoliveira.com/mechanism_breathing.html

Lung volumes

Lung volumes are directly measured. The average adult lung can fill to 6 litres of air, but only a small amount if used during normal breathing. The breathing mechanism is called respiration. The average adult breathes between 12-20 times a minute.

Tidal volume

Larger volumes	Smaller volumes
taller people	shorter people
non-smokers	smokers
people who live at higher altitudes	people who live at lower altitudes

A person who is born and lives at sea level, usually has a smaller lung capacity than someone who may live up on a hill. This is because the oxygen level is lower than up on a hill.
http://en.wikipedia.org/wiki/Lung_volu

mes

Vital capacity

This is the maximum amount of air which can be forced out of the lungs after maximum inspiration. This volume can be around 4,8000cm3. The volume can be measured by a spirometer. With other mental measurements, it can make a diagnosis of an underlying lung disease. An average adult has a capacity of 3 – 5 litres.
http://en.wikipedia.org/wiki/Vital_capacity

Residual volume

Typically, the lungs are never completely empty of air. If they were, the lung may collapse. The air which is left inside your lungs after maximal expiration is called residual volume. In an average human, the volume can be around 1,200cm3.

Control of breathing
Neural
Breathing may seem very simple, although it is very complex. It involves neurones, cells (conduct nerve impulses) and parts of the brain stem.
Chemical control
These factors are continually changing levels of oxygen and carbon dioxide. These are found in the medulla and in the aortic arch.
BTEC National Sport Level 2 Book 1
http://www.springerlink.com/content/t500027n53745l8t/
http://www.eurosiva.org/Archive/Goteborg/Abstracts/dahan.htm
http://www.nda.ox.ac.uk/wfsa/html/u02/u02_011.htm